

The unfettered foot: a paradigm change for equine podiatry

Tomas G. Teskey, DVM

8075 E. Bloomfield Rd.
Hereford, AZ 85615 USA

Abstract

The present day paradigm of equine hoof care fails to both define and solve some of the most common health problems seen in the equine industry. Traditional hoof care methods are unable to maintain soundness, nor bring lasting relief to ailing horses due to reliance on traditional farrier methods which are incompatible with the normal physiologic needs of equine species. The new paradigm of hoof care respects the hoof's ability to protect sensitive inner structures, adjust itself in response to the environment, promote proper circulation, exfoliate old tissue, replace itself over time and have a keen ability to sense the environment. Application of steel shoes prevents all of these vital functions and alters the form of hooves to such severe degrees that shod horses can not be deemed sound. Instead of providing the hoof protection, support and traction, steel shoes promote weakening and deterioration of the hoof, disrupt natural support mechanisms and disallow normal traction on all terrains. Protection for the hoof should be afforded the horse through the use of boots made of dynamic materials which complement the nature of the hoof. Veterinarians and other equine professionals are obligated to examine the evidence that shoeing horses is harmful and replace traditional hoof care practices with techniques that keep horses sound, return lame horses to health, and abandon the use of nailed on shoes, thus doing no harm to the animals.

Keywords: equine shoeing, farriers, natural hoof, hoof biodynamics, hoof physiology

Primum non nocere ("First, do no harm")
Attributed to Hippocrates c.460-357 B.C

Equine veterinarians have a responsibility to study the evidence that shoeing is harmful to horses [1-31]. At graduation, we swear an oath to use our knowledge to enhance animal health and we accept, as a lifelong commitment, the obligation to continually improve our knowledge and competence.

In the last eight years, a quantum leap has been achieved in the understanding of hoof care. In the words of the old song, the speed and distance of the leap has left many veterinarians and farriers feeling "bewitched, bothered and bewildered." The result is that, for a period of time yet, a widely stretched spectrum of

professional opinion will exist, together with some tension, concerning what is considered to be appropriate hoof care. At the traditional end of the spectrum, are farriers who combine their knowledge of hoof anatomy with blacksmithing skills to provide a metallic system of hoof care that has been firmly in place for over a thousand years. At the opposite end of the spectrum is the new paradigm that first emerged in the closing years of the 20th century. These are barefoot systems of hoof care initiated by two pioneers, a veterinarian, Hiltrud Strasser, and a farrier, Jaime Jackson. They are based on and nourished by knowledge gained by research, observation and trimming to provide physiologically acceptable, non-metallic systems of hoof care [2,4,10,15-17,28-29].

Many farriers, and many veterinarians who have previously obtained farriery credentials, remain ardent advocates of shoeing. Though they condemn their craft with faint praise when they concede that shoeing is a necessary evil, they revoke this weakness by citing the millennium-long history of shoeing, under management strictures imposed by non-leisure usage, as evidence that horses suffered no ill effects from such a practice [18].

The farrier-cum-veterinarians are fighting a rearguard action to defend the metallic end of the spectrum. Feeling the need to stay loyal to their first profession and its traditions, they are finding it difficult to defend their position in the face of an increasing army of knowledgeable horse owners who have studied barefoot hoof care. It is easy to sympathize with their dilemma. As more and more horse owners demonstrate success in working their horses without steel shoes, unheeding farriers and veterinarians alike will become increasingly uneasy at remaining entrenched in the metallic end of the hoof care spectrum. Utilizing the knowledge of natural hoof form and function as the basis for barefoot hoof care advances our success with horses, whereas holding fast to an untenable paradigm leaves hoof care mired in the past.

I am fortunate to have practiced at both ends of this spectrum. Having been raised and employed on working cattle ranches in Arizona, I learned from the wisdom of three generations how to shoe the horses in order to get the work done. These jobs demanded long hours of cross country riding, a chore I recall as being dictated by necessity rather than choice. I am now aware that it is not only possible, but preferable, more efficient, and healthier for horses to work barefoot.

Nevertheless, the entrenched opinion of most farriers and veterinarians is that horses are simply unable to work without shoes. It is more correct, however, to say that their *own* horses cannot work unshod, while others can. Their opinion stems from the retention of traditional thinking and, therefore, practices that have not appreciably changed over the past few decades. There are those that cling to tradition by portraying modern-day shoeing as advanced and no longer the harmful practice it was, speaking of "new shoeing methods" or even using another odd term, "natural principled" shoeing. But with awareness of hoof

biodynamics and of how and why horses can be trimmed and managed barefoot, these opinions are refuted. In their place emerges a paradigm for hoof care that enhances the welfare of the horse.

I submit that any acceptable method of hoof care should provide the hoof capsule with the ability to:

- Flex and torque in all directions in response to changes in terrain
- Assist in the movement of blood and lymph through weight-driven pump mechanics
- Protect sensitive inner structures from physical and environmental variables
- Exfoliate itself in a process that eliminates old and stimulates new growth
- Transfer sensory information about the environment to the central nervous system

Such criteria are met by the unfettered foot: a marvel of engineering that accomplishes these tasks by virtue of a wise and intelligent design. It possesses structures based on three very strong shapes...a cone-shaped inner and outer wall and coffin bone, a dome-shaped sole and coffin bone, and a triangular frog and bar-heel [Fig's 3-8]. This arrangement is healthy and helpful to the horse only when the hoof can shape itself by movement or be sculpted appropriately by tools and remain in a dynamic state. Inappropriate sculpting or the attachment of shoes impedes all these functions and, to varying degrees, hurts every hoof and harms every horse.

Forcing the flexible hoof to function when restricted by a rigid, steel shoe is one powerful prescription for promoting the hoof's deterioration. It results in deformity of the hoof and other nearby tissues, disrupts physiological processes, and leads to harmful overgrowth of the hoof capsule [Fig's 9-11,22,24]. Such trims do not respect the shape conducive to optimal hoof performance. When a shoe is finally removed, the overgrown hoof is trimmed in a manner designed to ensure the retention of the next shoe, rather than comply with the physiology of the hoof. [Fig's 12,16,18]. Additional harm follows; as such trims do not respect the shape conducive to optimal hoof performance.

Though iron, a thousand years ago, was utilized as the material of choice to prevent hooves from wearing down, we now realize that hooves are harmed when fixed in space due to the rigidity of metal, and fixed in time due to the normal growth of horn no longer being exfoliated. A review of my clinical records in equine veterinary practice over the past ten years has revealed that 85% of hoof and leg ailments of all kinds have occurred in shod horses, including catastrophic limb fractures. Yet the prevalence of shod horses amongst my

clientele during that time was only 48%. The hoof capsule is a highly evolved and specialized skin. Steel has no redeeming qualities as a material for protecting skin.

Shod horses have historically represented what has been thought of as a “higher level” of care in my area and throughout the equine industry, receiving “better” nutrition, housing and management than barefoot horses. However, in my practice, the incidence of limb disease and injury is 70% higher amongst shod horses. Shod hooves cannot adequately dissipate forces of torque and concussion. Instead, these forces harm the hoof and are also referred up the limb to assault other structures that have not evolved to withstand these stresses and strains. The resultant harm to the horse’s flesh and bone is both predictable and inevitable.

So common are hoof deformities in our daily clinical experience that many veterinarians accept them as normal. But up-right cylindrical hoof capsules; with high, contracted heels; long toes; flat, oval soles; and relatively horizontal hairlines represent common and severe deformities. Normal hooves have sloping, conical capsules; with low, expansive heels; short toes; domed, round soles; and 30 degree hairlines [Fig’s 1-8]. Many veterinarians blame the poor shape and condition of horse's feet today on genetic flaws, arguing that steel shoes are necessary to prevent further deterioration and breakage. But the evidence points to a simple environmental reason for the flawed feet of our domesticated horses ... an overall lack of movement of both horse and hoof. Foals, from the time they are born, are often confined on soft footing instead of being allowed to walk and run on firm terrain. The foal’s feet are not shaped by the natural wear that should start in the first few days of life [19]. Though we know that bone mass increases until four or five years of age, many horses are shod at one or two years old. Many adults continue to live sedentary lives and receive improper trimming and/or are regularly shod. Any combination of the above variables results in hoof deformities and small feet for the horse’s size. Horses rarely inherit poor feet. They develop poor quality, atrophied feet due to improper trimming, confinement, and shoeing. My observations indicate that foals born from “genetically small-footed” parents with deformed feet have beautiful, appropriately sized feet when trimmed properly from a young age, allowed adequate movement, and kept barefoot [Fig’s 14-15, 17-18].

Steel shoes weaken the hoof capsule. Preparation of a hoof for shoeing begins the weakening process by removing its strong, natural shape. A normal hoof is not flat in any plane, having naturally arching quarters [Fig. 1], recessed bars and sole [Fig’s 4-6]. But these important shapes are eliminated to permit the secure application of a shoe [Fig’s 12,18]. A horse left barefoot, but trimmed as for shoeing, has poor hoof form, an uncomfortable gait, and impaired hoof function. Such improper trimming leaves an owner with the impression that their horse “can't go barefoot.” The abnormally high pressure on bars and sole harms the hoof, as well as other portions of the limb and the whole of the body. With the

shoe applied, the hoof incurs further harm through contact of the shoe with the outer wall. The outer wall has evolved to fulfill a function that is primarily protective rather than weight bearing. Increased concussion and constant pressure on the outer wall causes the commonly seen rippling and buckling of horn tubule [Fig's 9,16] and disrupts the normal flow of the outer wall relative to the inner wall [17,20]. The transfixing metal nails course along the distal aspect of the inner wall, transmitting the excessive and harmful concussive force from the shoe through these areas. This breach of external surfaces results in mechanical disruption of the hoof wall, an unavoidable degree of laminar separation, the invasion of saprophytic bacteria and fungi, and exposure of the hoof to extremes of temperature. In addition, shoes inhibit the pumping system that promotes full circulation in the hoof, so reducing shock-absorbing ability [1,21]. It is also easy to appreciate how this ischemia interferes with normal horn growth and metabolism. A congested physiology, with resultant dysplastic, weakened growth is the result, leading to the severe hoof deformities and leg diseases we see in daily clinical practice.

Shoes provide such an effective barrier to sensation that their presence automatically debar a horse from being declared sound at any speed. The definition of a sound horse should be one free from pain that can walk, trot and canter with animation and impulsion, on unfettered feet.

In my experience, the terms "therapeutic" and "corrective" shoeing are oxymorons. Five years ago, I observed and provided reluctant veterinary support for a gelding that had prolapsed both coffin bones through the soles of his front feet and, at this late stage, was finally being managed on a barefoot hoof care program. Seven months later, this gelding was being ridden, never having had anything nailed to his feet to 'support' him through the ordeal. I was accustomed to forecasting one and a half to two years of healing time when applying the protocol of the Equine Digital Support System (EDSS), having seen several master farriers use this system on about fifty such cases. I noticed these horses grew what appeared to be new hooves, but upon removal of the EDSS appliance they were still unable to walk normally. When I learned about some barefoot trimming techniques, I discovered the problem. Realizing that healthy horses are suspended by their hoof capsules rather than supported by their soles, it became clear that EDSS and other shoeing protocols encourage horn growth that remains highly dependent on solar support, [Fig's 10,24] ignoring the need to develop strong laminar suspension. I quickly discovered that barefoot trimming techniques, boots, and a respect for the normal physiology of the hoof allowed these horses to grow durable structure with strong suspension. To "therapeutically" shoe them was contraindicated. Healing in a natural manner minimized the redundant tissue repair and metabolic stresses that otherwise the horse's body had to endure. In this way, feet regained their normal shape and outperformed shod ones in a shorter time, becoming honestly sound.

Users of EDSS and other shoeing systems often advocate that the heels of laminitic and foundered horses should be elevated above their physiological height [22,23]. I trust that this regrettable procedure will soon be discontinued, because laminae become even more stressed and ischemic when heels are elevated beyond physiologic parameters [Fig's 21,24]. The belief that deep digital flexor tendon tension must be "slackened" to prevent further coffin bone separation is erroneous. Mathematical equations and structural models indicate that it is primarily the weight of the horse on a coffin joint with higher than normal heels, not deep digital flexor tendon tension, that leads to coffin bone rotation [17]. The majority of foundered horses have deformed heels that are already too long. To elevate them even higher is contraindicated and harmful. It robs the horse of the strength and attributes of normal hoof form and is contrary to the normal biomechanics of the hoof. It causes decreased circulation, desensitization, severe hoof contraction, coffin bone deterioration and worsening separation. Surgical transection of the deep digital flexor tendon adds insult to injury, as it needlessly disrupts one of the important anatomical components offering dynamic support in the caudal region of the foot. Foundered horses can be properly managed through respectful sculpting of their hooves and the judicious use of boots and firm, nonconcussive terrain. What the inventors of the EDSS appliances intend, and what the EDSS patients in my practice develop, is wildly different.

Other examples abound, such as horses with typical navicular type pain at age two, to teenage horses with the more classical 'navicular' syndrome [24]. When properly managed barefoot, such affected horses often achieve honest soundness, and this at a time when traditional veterinary care claims no cure for such a condition. Navicular problems are absent in horses that have been trimmed for optimum hoof form and function from day one and allowed freedom of movement. Instead of investigating these shining examples and examining these case histories, most equine practitioners continue to use drugs, special bar shoes and surgical neurectomy to attempt a "cure". All such affected horses can be seen to have obvious deformities of their hooves [Fig's 9,11,15,18,20], yet the drugs and shoes prescribed do nothing to provide these horses with better hoof form. A sad situation exists when large amounts of resources and money are spent on misguided "therapeutic" or "corrective" treatments that are contrary to the physiology of the hoof and only serve to progressively worsen the horse's condition.

The increasing body of evidence about barefoot rehabilitation techniques and the demonstrably convincing performance of barefoot endurance horses are both fascinating and compelling. Other veterinarians that both ride and shoe cite the "impossibilities" of riding barefoot. I can only say that my own and thousands of other horses can and do ride barefoot, for hundreds of miles a week, on rocks, without steel shoes. [Fig's 7,23]. Clearly, domestic equine hooves can be conditioned beyond a level that is customary in feral horses. Four short years ago, I lacked the knowledge of proper hoof form and function and, as a result, I

was unable to salvage many horses with devastating hoof problems. It was the shoeing and the subsequent progressively debilitating hoof deformities in these horses that brought them to their end. I realized I could not, in good conscience, continue to use steel appliances to bring “healing” to hooves that were deformed due to the use of such appliances in the first place. Now the horses I see with similar problems improve in a short time. The knowledge of normal hoof form and function is powerful. Using it to prevent hoof deformities beats rehabilitating deformed feet any day, and is the key to honest hoof health. Pete Ramey is another enlightened ‘former farrier’ who no longer uses metal. He writes, “Our goal continues to be for every horse to outperform its former shod self, and the hooves deliver this with shocking consistency that amazes me more every day [25].”

Other common but unsound arguments claim that shoes are needed because of the added weight of tack and rider, the harder terrain, and the extreme sports that are expected of the modern-day horse. Each of these arguments can be refuted, in order, on physiological and historical grounds. For example, the feet of pregnant mares comfortably adapt, in the wild, to the increased weight of the gravid uterus. Horses adapted to varied terrains, including desert, where hard terrain is the norm. The ‘extreme sport’ of cavalry warfare was conducted for about 2500 years without shoes. For the last two hundred years of this period, horses were carrying the ‘added weight’ of armor and equipment. We should recognize that, on weight bearing, steel shoes hold the sole of the hoof in a non-weight-bearing, vaulted position against the descending coffin bone. We misinterpret so-called “stone bruising” of the soles of shod horses as being caused by stones on the ground. This pattern of bruising originates from concussion followed by pressure necrosis of solar corium that cannot escape the blows of the coffin bone above and an unyielding sole beneath [Fig’s 12-13]. Bruising of the moonsickle (a) points to a pathology at the tip of the coffin bone and (b) originates because of excessive heel height [Fig. 24]. Another example is the almost ‘epidemic’ incidence of ringbone among shod horses in my practice. With or without extra weight, shod hooves are disallowed vital flexion and torsion, forcing the proximal interphalangeal and other joints to torque unnaturally. Add to these stresses the greatly increased concussive forces from the shoe below [17,19,26] and the weight above, and it inevitably follows that nailed-on shoes are a prescription for disease. It becomes obvious that the more extreme or demanding the sport is, the more important it becomes to have normal, unfettered feet that can perform for the horse and rider.

The provision of movement is an important factor in a bare-foot management program [2,15,17,19,27,28]. The ideal is turn-out 24/7 with companion horses on terrain that, at least in part, matches the ground on which they have to work. But where movement cannot be provided, such as for horses in more urban environments where turnout space is limited, they are still much better off barefoot than shod. All horses should be provided with dry or well-drained footing whether kept in confinement or on several acres of pasture but firm, dry footing is

mandatory for those that are confined. Daily riding or lead exercise is especially critical for the confined horse. Similarly, when confined, frequent trimming of the hooves is essential to prevent the onset of imbalances, cracks, infections and overgrowth. Physical confinement does not necessitate shoeing, but it does necessitate more regular and careful attention to the hooves and, when riding on rough terrain, the use of boots [Fig. 19]. If the unshod feet of stalled horses are cared for, as outlined, they can remain healthy and sound. To achieve this goal some simple changes in management become necessary.

My own and other barefoot horses have hooves that wear slower than steel shoes over a given period of time. If at first that seems “impossible”, stop and appreciate the critical variables that are the allies of the barefoot horse: time, wear, growth, callusing and a dynamic existence. Their “unprotected” hooves grow overnight in response to the wear they receive between daily rides, whereas shod horses are unable to help themselves with hoof growth or balance and are totally dependent on the shoes which transfix their hooves in a predetermined plane. Other interesting comparisons can be made on the basis of speed, agility and degree of soundness.

Proprioception is significantly impaired in shod horses [17]. Through lack of sensory feedback, they pay less attention to where their feet are landing and suffer more trauma from interference, slipping and stumbling on rocky terrain. Having a normal (i.e., highly sensitive) feedback system, barefoot horses are more agile, watch where they are stepping, avoid rocks, and rarely stumble. Due to the superior traction of a yielding hoof, neither do they slip and slide. The result is healthy, but minimal hoof wear and a safer, more enjoyable ride for them and their passengers. Those who ride shod horses on rocky ground know how dangerous it is. Those who have experienced the confidence of a barefoot horse in such terrain are most reluctant to get back on a shod horse.

I have documented a decreased incidence of heart murmurs and lower resting heart rates in my own barefoot horses, as well as in many barefoot endurance horses. Their cardiovascular fitness, as judged by cardiac recovery measurements, is superior compared to shod horses doing similar work.

One of the most compelling examples of the underlying un-soundness of all shod horses is the crippling lameness that quickly follows the loss of a shoe. This becomes a serious problem when miles from home and nails or appropriately sized boots are unavailable. If shod horses suffer no ill effects from their shoes, as many professionals contend, why are they so lame within minutes when walking a short distance without them? Again, the earlier proposed definition of a truly sound horse comes to mind.

Sound, barefoot horses, when allowed movement over a suitably demanding terrain, often trim their own feet. This is the most ideal trim they can get. But many still need trimming despite having been worked on rough terrain. Though I

have mentioned little about how barefoot trimming is performed, the above two sentences provide the key. A barefoot trim sculpts the horse's hoof by mimicking the effects of mileage [Fig's 5-6]. If occasions arise in which hoof wear does exceed growth, boots allow the work to get done.

Boots provide an outstanding option for honest hoof protection, being made of dynamic materials that move and recoil to complement a hoof capsule's function [25,29]. They are especially helpful in this transition age of hoof care, in which the need to rehabilitate hooves harmed by shoeing is omnipresent. The number of new boot designs that have been marketed in the last five years has tripled, and the demand for new and user-friendly designs is increasing to the point where supply some-times fails to meet demand [Fig 19]. Nevertheless, riders find that the more they work with properly trimmed and conditioned horses, the less are hoof boots needed. "These days," says Pete Ramey, "I have traded in my metal shoes for state of the art hoof boots, and I have learned the awesome power in allowing the 'off season barefoot healing period' to extend throughout the horse's life [25]." It is ironic that the iron shoe we once thought offered protection, support and traction is now known to expose the hoof to harm, deprive it of support, and render it incapable of providing proper traction. And these are only a few of the harms that a shoe inflicts.[11] There just aren't any good excuses for nailing rigid steel shoes to horses' hooves, recommending their use, or standing idly by while they are used. As veterinarians, we should be advocating what is healthiest for the horses under our care.

Barefoot hoof care works exquisitely well with the natural horsemanship philosophies of today, and the welfare of the horse is enhanced. As in any work with a horse, "asking" in-stead of "telling" becomes our guide for trimming a hoof. Horses are only too happy to perform with their bodies and spirits intact. That spirit of the horse always keeps us coming back for more. As hoof care specialist Martha Olivo remarks, "Horses and I just 'find' each other...we always have. They have been my best teachers and at many important levels, we keep each other whole."

It is a grave mistake for 'entrenched' veterinarians to comfort themselves with the belief that the barefoot movement is inapplicable to horses in certain situations or no more than a passing fad. It dismisses the fact that this body of knowledge is securely based on a respect for the horse's inherent genetic endowments. If we nurture their physiological inheritance, horses are perfectly able to complete a longer, more fruitful, lifetime of work. Keeping horses barefoot is a phenomenal win-win situation, offering increased vitality and performance. Though I can continue to write about these facts, others must do their own research and use their own observational skills if they wish to arrive at the same understanding.

Championing the barefoot cause allows us to comply with the oath we took on graduation. Barefoot methods of hoof care stand firm on a sound body of knowledge. Farriers and veterinarians are the best men and women to promote

this movement as they have the necessary broad training, the clientele, the love for the horse, and the tools. The primary objective is to improve the welfare of the horse by carefully applying barefoot (i.e., physiological) management programs. Happily, this brings its own secondary rewards, as such work is not only more successful and professionally satisfying than the traditional approach but it is physically less strenuous and safer. For the cooperating farrier it actually extends his business, as most owners would prefer not to do their own trimming. The former farrier KC La Pierre tells his audiences that shoeing is not, as claimed, a necessary evil. The evil arises, he says, from our lack of understanding of the hoof. It is this that leads to the belief that shoeing is necessary. Julian Huxley expressed the same thought in five words, "... false thinking brings wrong conduct."

The currently divisive spectrum of hoof care will be less polarized in the future. Similarly, organizations can expect sports activities that depend solely on specialized shoeing techniques to wane. Slider shoes that allow for exaggerated sliding stops, gait-altering shoes that interfere with normal hoof flight arcs, racing plates with grabs that increase the incidence of injuries, and other appliances that are used strictly for fashion will be replaced with barefoot trimming techniques and/or boot designs that do no harm.

We are professionals, pledged to advance our knowledge and competence and offer it to people who count on us, without restraints of ego or tradition. Science is a self correcting system and, though the corrections are often sadly delayed, they do eventually take place. For example, we no longer fight disease by blood-letting: the practice of pin-firing and the use of caustics is on the wane: medial patellar desmotomy is largely a surgery of the past: and we now know that riders can communicate better with their horses if the bit is removed [30,31], metal in the mouth being the cause of over a hundred behavioral and medical problems. Clients will come to us to find out about barefoot hoof care, to discover how their horses can improve their performance, and become less prone to a whole host of problems when barefoot. Veterinarians should be aware that there is a growing dissatisfaction among horse owners with the traditional hoof care options that are currently being offered by the profession. Already the climate of opinion among knowledgeable horse owners is such that an owner whose veterinarian has overlooked, ignored, refused or failed to offer them the barefoot option might construe such an omission as an act of negligence.

All of us want nothing less than faster, more complete healing for our equine patients. We would do well to take seriously the evidence clearly indicating that horses should not be shod. Taking the lead in promoting healthy hooves, educating ourselves, and our veterinary students, is a worthwhile, rewarding project and it is one that we have a responsibility to adopt. Those who resist shouldering this responsibility will soon find themselves corralled by horse owners who have a better understanding of the horse's foot than they do.

Conclusion

The shod and deformed foot is a sad and sorry sight, harmful to the horse.
The bare and healthy foot is a joy to behold, and does no harm, of course.

References

- [1] Pollitt C. Clinical Anatomy and Physiology of the Normal Equine Foot. *Equine Veterinary Education*, 1992;4:219–24.
- [2] Jackson J. *The natural horse*. Star Ridge Publishing, Harrison, AR, 1997.
- [3] Cook WR. Educated owners and barefoot horses: An open letter to veterinarians. *Journal of Equine Veterinary Science*, 2001;21:471–3.
- [4] Strasser H. Video: Optimum Hoof Form - The Basic Trim. 2002. Available at www.strasserhoofcare.com.
- [5] Cook WR. Leave nothing but footprints ... and fertilizer. *Trail Blazer Magazine*, May 2002:13.
- [6] Welz Y. Hoofcare for the Millennium. 2002. Available at www.thehorseshoof.com/tufts.html.
- [7] Cook WR. Professional dismissiveness of equine barefootedness. *Journal of Equine Veterinary Science*, 2003 Dec: 564–6.
- [8] Simons L. Rethinking traditional hoofcare: the Strasser theory flies in the face of mainstream farrier logic. 2003. Available at: www.hoofcare.com/contents74.html.
- [9] Welz Y. The changing face of hoofcare in the United States. 2003. Available at www.thehorseshoof.com/hoofcareus.html.
- [10] Strasser H. Who's afraid of founder?: Laminitis demystified. Edited and translated by the publisher, Sabine Kells, Qualicum Beach, BC, Canada, 2003.
- [11] Welz Y. *Barefoot Stories: Featuring the Strasser Method of hoof care*. Sabine Kells, Qualicum Beach, BC, Canada, 2003.
- [12] Speckmaier P, Kells S. *The Centaur Reborn: Holistic horsemanship and the foundation for optimal performance*. Sabine Kells, Qualicum Beach, BC, Canada, 2003.
- [13] Cook WR. Get a grip. Published online at www.bitlessbridle.com and a shortened version "Remove the shoes" published in the *Thoroughbred Times*, September 6, 2003;19(36):18.
- [14] Cook WR. Horseshoes totally indefensible. *Journal of Equine Veterinary Science*, 2004;24:266.
- [15] Strasser H, Kells S. *A lifetime of soundness*. Sabine Kells, PO Box 44, Qualicum Beach, BC, Canada V9K 1S7. 1998.
- [16] Strasser H. *Shoeing: A necessary evil?* Kells S, ed. Sabine Kells, PO Box 44, Qualicum Beach, BC, Canada V9K 1S7. 1999.
- [17] Strasser H, Kells S. *The hoofcare specialist's handbook: Hoof orthopedics and holistic lameness rehabilitation*. Sabine Kells, PO Box 44, Qualicum Beach, BC, Canada V9K 1S7. 2001.

- [18] Jochle W. Use defines shoeing. *Journal of Equine Veterinary Science*, 2004;24:122–3.
- [19] Bowker R. The Growth and Adaptive Capabilities of the Hoof Wall and Sole: Functional Changes in Response to Stress. American Association of Equine Practitioners, Lexington, KY. Available at www.ivis.org/proceedings/aaep/2003/toc.asp, Internet Publisher: International Veterinary Information Service, Ithaca NY, 2003.
- [20] La Pierre KC. The chosen road: Achieving high performance through applied equine podiatry. Naked Greyhound Press Dover DE, 2004.
- [21] Bowker R. A New Theory About Equine Foot Physiology. March 6, 1998. Available at <http://cvm.msu.edu/news/press/footphy.html>.
- [22] Ovnicek G. New Hope for Soundness. Wild Horse Publishing, Florence, CO, 2004. Available at <http://www.whpublishing.com/store/products.html>.
- [23] Redden R. Instructions for Redden Modified Ultimates, State of the Art Treatment for Laminitis, 2004. Available at <http://www.nanric.com/ULTIMATE.html>.
- [24] Bowker R.: New Theory May Help Avoid Navicular. March, 1999. Available at <http://cvm.msu.edu/news/press/navicular.html>.
- [25] Ramey P. Making natural hoof care work for you. Star Ridge Publishing, Harrison, AR, 2004.
- [26] Strasser H, Kells S. Listing of the harmful effects of shoeing. 2002. Available at www.thehorseshoof.com/listing.html.
- [27] Jackson J. Horse owners guide to natural hoof care. Star Ridge Publishing. Harrison, AR, 2002.
- [28] Jackson J. Founder: Prevention & cure the natural way. Star Ridge Publishing. Harrison, AR, 2002.
- [29] Jackson J. Guide to booting horses for hoof care professionals. Star Ridge Publishing, Harrison, AR, 2004.
- [30] Cook WR. On talking horses: barefoot and bit-free. *Natural Horse Magazine*, 2001;3(19).
- [31] Cook WR. On 'mouth irons', 'hoof cramps', and the dawn of the metal-free horse. *Natural Horse Magazine*, 2002;4(4).

Figure 1: Natural arch in quarter complements internal anatomy.



Figure 4: Domed sole and weight bearing frog between low expansive heels.

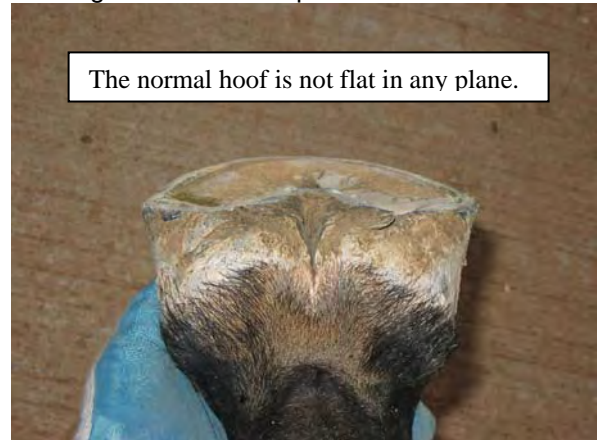

Figure 2: Passive arch in quarter, sloping hairline and equal toe and heel angles.

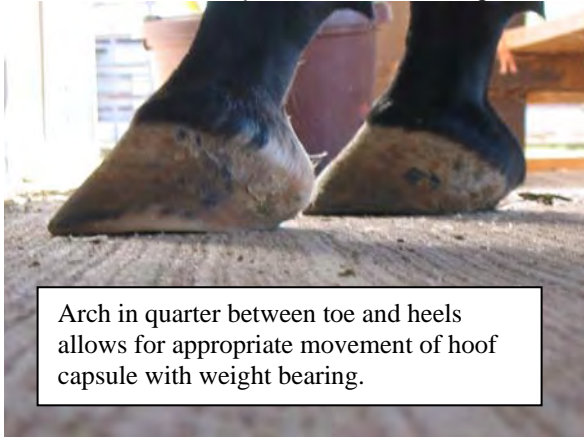


Figure 5: Arch in quarters and domed sole pre-trim.



Figure 3: Cone shaped hoof capsule, rounded toe, smooth wall.



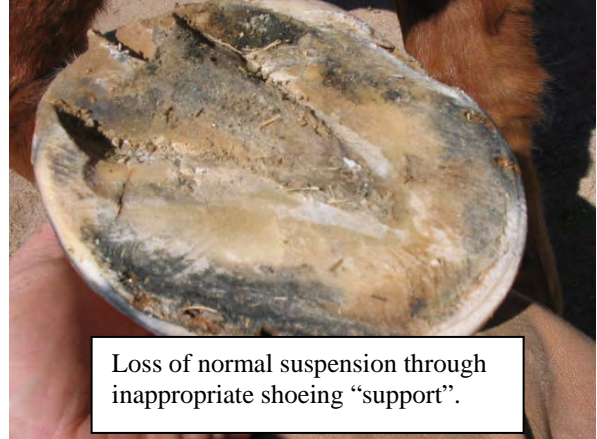Figure 6: Domed sole after natural trim mimicking natural exfoliation.



Figure 7: Triangular frog and bar-heel self-trimmed through movement.



Figure 10: Collapsed/flattened deformity of sole from pads and shoeing "support".



Loss of normal suspension through inappropriate shoeing "support".

Figure 8: Large triangular frog and bar-heel. Natural (physiologic) trim with tools.

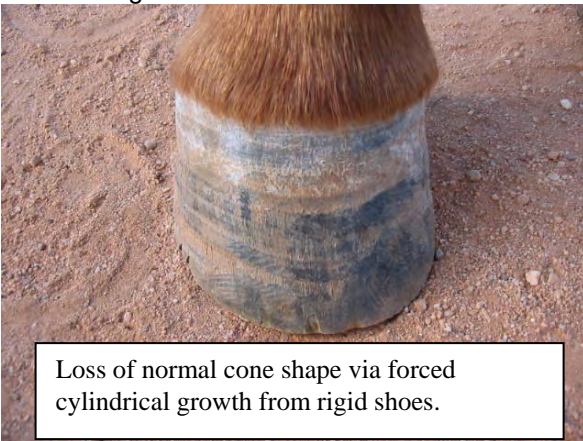


Normal spade-shaped rear hoof.

Figure 11: Severely atrophied and deformed frog and bar-heel triangles.



Figure 9: Cylindrical deformity of hoof capsule and concussive damage from shoeing and lack of movement.



Loss of normal cone shape via forced cylindrical growth from rigid shoes.

Figure 12: Fixed in two-dimensional space with shoe, inactive frog and prevention of independent heel movement.



Figure 13: Uniform bruising from inability of sole to yield to descending coffin bone.



Figure 16: Damage from nails and concussion and general hoof atrophy.



Figure 14: Non-contracted four year old (full brother to Fig. 15) never shod and allowed movement (not stalled).



Figure 17: Low, expansive, supportive heels allowed independent rear suspension when unshod and in good form.



Figure 15: Seven year old (full brother to Fig. 14 kept in same pasture) with hoof contraction strictly from shoeing.



Figure 18: Unyielding heels disallowed independent movement when shod, leading to atrophy and pinching.

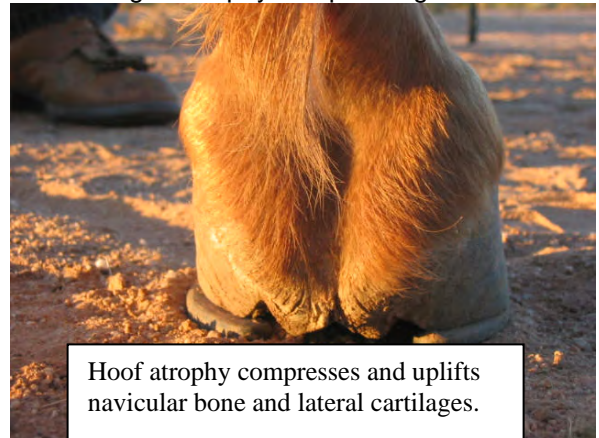

Figure 19: Dynamic hoof protection comes in the form of boots that flex, complementing hoof mechanism.



Figure 22: Harmful, cylindrical overgrowth due to presence of rigid shoe and flattening of normal solar dome.

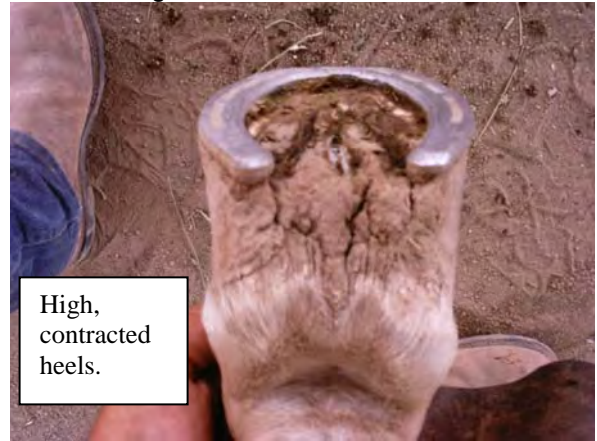

Figure 20: "Corrective shoe" next to hoof one year after removal of shoe showing achievement of heel expansion.



Figure 23: Hooves can handle rough terrain and are naturally trimmed and callused through movement.



Figure 21: Inappropriate heel elevation in laminitic horse leading to further damage of dorsal laminae.

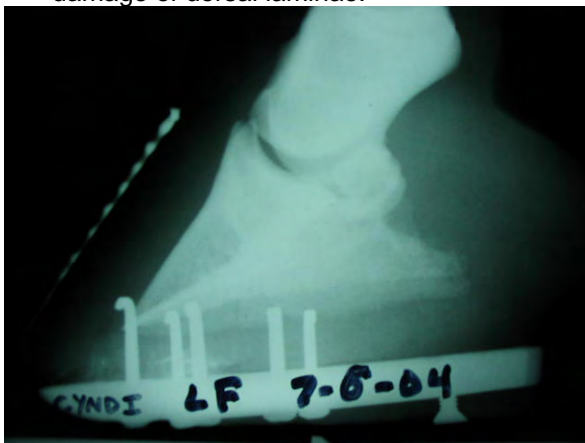


Figure 24: Inappropriate trimming and shoeing leaves heels too high, with more horizontal hairline.

